

The effect of vertical skeletal pattern in the buccal corridor area show during posed smile

Afeef Umar Zia^a, Amjad Mahmood^b, Haroon Shahid Qazi^c

Abstract

Introduction: Emergence of soft tissue paradigm in clinical orthodontics has made smile analysis and designing key elements in treatment planning. Smile is an integral constituent of the facial attractiveness of a person. Various factors influence smile. The smile frame work is influenced by gingival display during smiling, incisors display and the buccal corridor space. Buccal corridor area show according to many influences smile immensely.

Material and Methods: Lateral cephalograms were taken with patient's Frankfort Horizontal plane parallel to the floor, unstrained lips and teeth in centric occlusion. Radiographs were traced. Ratio between lower anterior facial heights to total anterior facial heights were recorded on the patient's data form to establish the vertical skeletal relationship of the patients. This ratio was correlated with the increased or decreased buccal corridor show during posed smile by applying the Pearson correlation coefficient. Data was analyzed on statistical package for social sciences (SPSS version 10). Descriptive statistics were used. Mean \pm S.D was calculated for age (in years), vertical skeletal pattern value and the buccal corridor area of subjects.

Results: The range of ratio of lower anterior facial height to total anterior facial height (in degrees) was 48° to 67° with a mean of 56.357° and standard deviation of 3.59°. The relationship of ratio of lower anterior facial height to total anterior facial height (in degrees) with buccal corridor area show (mm) was significant (P-value < 0.05). The results show that as ratio of lower anterior facial height to total anterior facial height (in degrees) increases the mean buccal corridor area show decreases.

Conclusions: Factors effecting buccal corridor area show must be kept in mind since it has an influence in the outcome of treatment. It is paramount to do so since most patients assess the outcome of their treatment by the attractiveness of their smile.

Keywords: Inter-commissure width; Inter-pupillary distance; Inter-pre-molar width

Introduction

Ideal soft tissues render balance in a face and confer beauty. Beauty is the phenomenon of experiencing pleasure through the perception of balance.¹ Facial attractiveness has various essential components including balanced skeletal bases, harmonious soft tissues, proportionate relationship between hard and soft tissues

and many others. The re-emergence of the soft tissue paradigm in clinical orthodontics has made smile analysis and designing, key elements in treatment planning. Conclusively, smile is an integral constituent of the facial attractiveness of a person.

Smile is considered the universal friendly greeting in all cultures. A wide attractive smile expedites easy psychosocial adjustability of the patient in the community around.² It is expressed as a result of pleasure, emotional agreement, amusement, a friendly gesture and to convey compassion. The importance of physical and facial attractiveness in which the smile plays a major role, has been studied and related to job recruitment decisions, initial impressions, susceptibility to peer acceptance, voting and

^a Corresponding Author: BDS, FCPS. Assistant Professor, Department Of Orthodontics, Islamabad Medical and Dental College, Bahria University, Islamabad. Email: afeefumarzia@gmail.com

^b BDS (Pb), FDS RCSEd (UK). Head Department Of Orthodontics, Margalla College Of Dentistry, Margalla Institute Of Health Sciences, Gulrez III, Rawalpindi.

^c BDS, MS. Professor and Head, Department of Orthodontics, Dental Section, Islamabad Medical and Dental College, Bahria University, Islamabad, Pakistan

juror decisions and social interactions.³ Gender, age and income among other factors have influenced people's perception of attractiveness of smiles.^{4,5}

Smile is of two types, posed and un-posed,⁶ the posed being considered in this study since it is reproducible. Posed smile also called as the social smile, is a voluntary smile a person uses in social gatherings or when posing in a photograph. 'Mini esthetics' is a sub-domain of diagnosis in the frontal examination of an orthodontic patient. It consists of the smile frame work, gingival display during smiling, incisors display and the buccal corridor space show. Many features are said to increase the pleasing effect of a smile or they render beauty to a smile e.g. consonance in a smile, appropriate gingival display, harmonious gingival scaffolding, colorful gingiva, minimal buccal corridors, appropriate incisal show during smiling and so on. All these add perfection to a smile. Many studies have been conducted with results confirming the above mentioned facts.^{7,8,9} Having minimal buccal corridors is a preferred esthetic feature for both men and women. Many hard and soft tissue factors influence the buccal corridor area show during posed smile e.g. lower anterior facial height ratio, inter-premolar width, inter-commissure width, arch form and lip length etc.⁹

The purpose of this study was to establish the correlation between the vertical skeletal relationship and the buccal corridor area show of a patient during posed smile. This can enable orthodontists to plan an orthodontic case keeping in mind the esthetic implications of the vertical skeletal pattern on buccal corridor area show.

Material and Methods

147 subjects were included in this study by non-probability consecutive sampling keeping in mind the inclusion criteria (n =147, 40 males and 107 female patients with excess, normal and insignificant buccal corridors).

Male and female patients of any age group seeking orthodontic treatment for all types of malocclusions with complete permanent dentition with no missing or supernumerary tooth (except third molars), symmetrical arch forms and normal upper lip length (19-22 mm)¹¹ were included in the study. Patients with facial asymmetry, temporo-mandibular joint disorders, cleft lip and palate or any other syndrome, undergone orthognathic surgery, active periodontal disease or patients undergoing any surgical periodontal procedure, severe malocclusion / cant of maxillary plane were excluded from the study.

Informed written consent was taken from the selected patients who were to undergo orthodontic treatment after taking permission for this study from the ethical committee of the hospital. To control the bias each measurement was verified by a colleague.

Lateral cephalograms were taken with patient's Frankfort Horizontal plane parallel to the floor, unstrained lips and teeth in centric occlusion. Radiographs were traced on 8 × 10inch standard translucent acetate tracing paper, over a standard illuminated view box with a lead pencil (# 2 ½ HB). Ratio between lower anterior facial height to total anterior facial height¹⁰ (Figure 1) were recorded on the patient's data form to establish the vertical skeletal relationship of the patient. This ratio was correlated with the increased or decreased buccal corridor show during posed smile by applying the Pearson correlation coefficient.

Data was analyzed on statistical package for social sciences (SPSS version 10). Descriptive statistics were used. Mean ± S.D was calculated for age (in years), vertical skeletal pattern value and the inter-commissure width of subjects. Frequencies and percentages were calculated for gender. Pearson correlation coefficient was determined for inter-commissure width, inter-premolar width, vertical skeletal relationship with the buccal

corridor area show. *r* value was determined between -1.0 and +1.0.

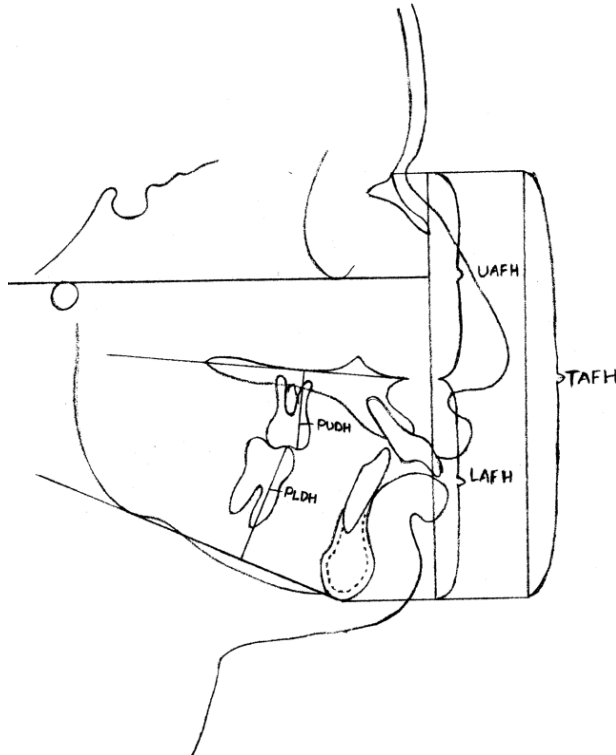


Figure 1: Ratio of lower face height to total anterior face height

Results

The buccal corridor area show on frontal smile was measured, the minimum being 0 mm and maximum being 4.50 mm. The mean buccal corridor area show was 1.799 with standard deviation of 0.9904 mm (Table I).

Table I: Buccal corridor area show (in mm on frontal smile)

	N	Minimum	Maximum	Mean	Std. deviation
Buccal corridor area show (in mm on frontal smile)	147	.00	4.50	1.799	.9904

The range of ratio of lower anterior facial height to total anterior facial height (in degrees) was 48° to 67° with a mean of 56.357° and standard deviation of 3.59° (Table II).

Table II: Ratio of lower ant. facial height to total ant. facial height (in degrees)

	N	Minimum	Maximum	Mean	Std. deviation
Ratio of lower ant. facial height to total ant. facial height (in degrees)	147	48.0°	67.0°	56.35°	3.591°

Table III: Correlation of buccal corridor area show (in mm on frontal smile) with ratio of lower ant. facial height to total ant. facial height (in degrees)

	Buccal corridor area show (in mm on frontal smile)	
	Pearson correlation	Sig. (2-tailed)
Ratio of lower ant. facial height to total ant. facial height (in degrees)	-.147*	.045

* Correlation is significant at the 0.05 level (2-tailed).

Table IV: Relationship of ratio of lower ant. facial height to total ant. facial height (in degrees) with buccal corridor area show (mm)

Ratio of lower Ant. facial height to total ant. facial height (in degrees)	N	Mean buccal corridor area show (in mm on frontal smile)	Std. deviation	p value
Less than normal	13	2.3846	0.61758	0.016
Normal	60	1.9125	0.92725	
Greater than normal	74	1.6047	1.04604	

The correlation of buccal corridor area show (in mm on frontal smile) with ratio of lower anterior facial height to total anterior facial height (in degrees) was negative and statistically significant. The Pearson

correlation coefficient was -0.147 (P -value < 0.05) (Table III).

The relationship of ratio of lower anterior facial height to total anterior facial height (in degrees) with buccal corridor area show (mm) was significant (P -value < 0.05). The results show that as ratio of lower anterior facial height to total anterior facial height (in degrees) increases the mean buccal corridor area show decreases (Table IV).

Discussion

A pre-treatment sample was selected for this study since it exemplified typical orthodontic patients requiring treatment. Since a pre-treatment sample was used, these subjects varied greatly. The variety in the sample provided a range of smiles and dentofacial discrepancies that was ideal in correlating the hard tissue structures to the resulting smile configurations. In this study more female subjects were present as the sample was not collected on the basis of gender.

As already mentioned, minimization of buccal corridor area show during posed smile is an integral component of problem list, treatment planning and goals.⁸ Smile is an important facial feature. It can be altered tremendously as a result of orthodontic treatment. Many studies have been carried out for the diagnosis and implications of buccal corridor area show during posed smile and the factors that increase or decrease it. Every effort should be made to minimize it.

Three groups were made on the basis of ratios of lower anterior facial height to total anterior facial height. Patients in which lower facial height to total anterior facial height ratio was 54% to 56% were put in normal group, patients having lower facial height to total anterior facial height ratio less than 54% were grouped in decreased LAFH and patients having lower facial height to total anterior facial height ratio more than 56% were grouped as increased LAFH.

For the values of the facial heights our values were less as compared to the values found in the study by Yang⁹ that came out to be 46.78° with a standard deviation of 6.17° whereas those found in McNamara's sample were slightly raised with a mean value of 59.7° and a standard deviation of 7.5° . Lower anterior facial height values varied with the amount of buccal corridor area show. But they also found that the vertical skeletal pattern of the lower face contributed to the change in buccal corridor area show where as the upper facial height that also contributes to the over all vertical pattern does not effect this phenomenon. One possible reason could be its relationship with the activities of the muscles of the lips which are only present in the lower half of the face. Hence it can be said that a longer face has lesser buccal corridor area show.

To standardize the subjects in normal anterior facial height group only those patients were included in this group who had the ratio of lower anterior facial height to total anterior facial height within the range given by study on white American male and female subjects^{11,12} as norms of white Americans are still used as a standard in cephalometric analyses and measurements. As far as distribution of sample according to LAFH is concerned, patients with increased lower anterior facial heights were more as compared to the patients in the other groups. This finding should be considered during treatment planning and deciding about types of mechanics and appliance so that extrusive or intrusive mechanics can be applied for altering the lower anterior facial height if it is in the lower than normal range.

Extrusive mechanics should be done in case of low angle cases, which include mechanics for the eruption of molars. Banding of second molars should be done in case of decreased lower anterior facial height in order to enhance the effects of bite opening mechanics.

Conclusions

There is significant effect of lower anterior facial height on the buccal corridor area show during posed smile and increased ratio results in a decreased buccal corridor area show during posed smile. By correcting lower anterior facial height, buccal corridor area show during posed smile can be brought into the normal range which ultimately results in the improvement of facial profile after orthodontic treatment.

References

1. Jahanbin A, Basafa M, Alizadeh Y. Evaluation of the divine proportions in the facial profile of young females. *Indian J Dent Res* 2008;4:19.
2. Jan HU. Restore a wide radiant smile without dental extractions. *Pak Oral Dental J* 2005;25: 65-8.
3. Desai S, Upadhyay M, Nanda R. Dynamic smile analysis: Changes with age. *Am J Orthod Dentofacial Orthop* 2009; 136:3-10.
4. Geron S, Atalia W. Influence of sex on the perception of oral and smile esthetics with different gingival and incisal plane inclination. *Angle Orthod.* 2005;75:778-84.
5. Kerosuo K, Al Enezi S, Kerosuo E, Abdulkarim E. Association between normative and self perceived orthodontic treatment need among Arab high school students. *Am J Orthod Dentofacial Orthop.* 2004;125:373-78.
6. Sarver DM, Proffit WR. Special considerations in diagnosis and treatment planning. In: Graber TM, Vanarsdall RL, Vig KWL (edi). *Orthodontics: Current principles and techniques.* 4th ed. St Louis: Mosby 2005:3-70.
7. Krishnan V, Daniel ST, Lazar D, Asok A. Characterization of posed smile by using visual analog scale, smile arc, buccal corridor measures, and modified smile index. *Am J Orthod Dentofacial Orthop* 2008;133:515-23.
8. Moore T, Southard KA, Casco JS, Qian F, Southard TE. Buccal corridors and smile esthetics. *Am J Orthod Dentofacial Orthop* 2005;127:208-13.
9. Yang H-II, Nahm DS, Baek SH. Which hard and soft tissue factors relate with the amount of buccal corridor space during smiling? *Angle Orthod* 2008;78:5-11.
10. Isiksal E, Hazar S, Akyalcin S. Smile esthetics: Perception and comparison of treated and untreated smiles. *Am J Orthod Dentofacial Orthop* 2006;129:8-16.
11. Proffit WR, Sarver DM. Diagnosis: gathering and organizing the appropriate information. In: Proffit WR, White JRP, Sarver DM (edi). *Contemporary treatment of dentofacial deformity.* 1st ed. St Louis: Mosby 2003:127-71.
12. Loi H, Nakata S, Nakasima A, Counts AL. Comparison of cephalometric norms between Japanese and Caucasian adults in antero-posterior and vertical dimension. *Eur J Orthod* 2007;29:493-9.